

## Original Article

# A Factor Increasing Venous Contamination on Bolus Chase Three-dimensional Magnetic Resonance Imaging: Charcot Neuroarthropathy

Mehmet B. Çildağ, Mustafa B. Ertuğrul<sup>1</sup>, Ömer FK. Köseoğlu, David G. Armstrong<sup>2</sup>

Department of Diagnostic and Interventional Radiology and <sup>1</sup>Infectious Diseases and Clinical Microbiology, Adnan Menderes University, Aydın, Turkey, <sup>2</sup>Department of Surgery, Southern Arizona Limb Salvage Alliance, University of Arizona College of Medicine, Tucson, Ariz, USA



Received : 23-10-2017

Accepted : 08-03-2018

Published : 05-04-2018

## INTRODUCTION

Advanced atherosclerosis accompanied with below-the-knee (BTK) arterial pathologies is a significant problem in diabetic patients with foot lesion and peripheral artery disease (PAD). Most diabetic patients, being asymptomatic due to peripheral neuropathy, receive treatment after diabetic foot lesion and critical leg ischemia development.<sup>[1,2]</sup> BTK arterial disease is the main cause of PAD with or without accompanying the proximal disease. The contribution of an ischemic event is shown in more than 40% of cases with diabetic foot lesion.<sup>[3]</sup> Conventional angiography has been the mainstay for many years and remains the gold standard due to its superior image resolution and being the only modality used for both diagnosis and treatment. However, magnetic resonance (MR) angiography has been used as a routine procedure for the imaging of extremity arteries and offers advantages over

conventional angiography.<sup>[4]</sup> It is noninvasive, patients are not exposed to ionizing radiation and potentially nephrotoxic iodinated contrast material. There have been major technical advances in recent years including three-dimensional (3D) contrast-enhanced MR angiography (MRA) and the development of moving table which enables whole limb examinations with single contrast injection. One of the important problems with this technique is venous signal below the knee, especially in patients with diabetes. Since in patients with diabetes, BTK arterial disease is characterized by long, multilevel disease involving all three infrapopliteal

## ABSTRACT

**Background:** The study aimed to evaluate the ratio of venous contamination in diabetic cases without foot lesion, with foot lesion and with Charcot neuroarthropathy (CN). **Materials and Methods:** Bolus-chase three-dimensional magnetic resonance (MR) of 396 extremities of patients with diabetes mellitus was analyzed, retrospectively. Extremities were divided into three groups as follows: diabetic patients without foot ulcer or Charcot arthropathy (Group A), patients with diabetic foot ulcers (Group B) and patients with CN accompanying diabetic foot ulcers (Group C). Furthermore, amount of venous contamination classified as no venous contamination, mild venous contamination, and severe venous contamination. The relationship between venous contamination and extremity groups was investigated. **Results:** Severe venous contamination was seen in Group A, Group B, and Group C, 5.6%, 15.2%, and 34.1%, respectively. Statistically significant difference was seen between groups with regard to venous contamination. **Conclusion:** Venous contamination following bolus chase MR was higher in patients with CN.

**KEYWORDS:** Charcot neuroarthropathy, magnetic resonance angiography, venous contamination

**Address for correspondence:** Dr. Mehmet B. Çildağ, Department of Diagnostic and Interventional Radiology, Adnan Menderes University, Aydın, Turkey. E-mail: mbcildag@yahoo.com

This is an open access journal, and articles are distributed under the terms of the Creative Commons Attribution-NonCommercial-ShareAlike 4.0 License, which allows others to remix, tweak, and build upon the work non-commercially, as long as appropriate credit is given and the new creations are licensed under the identical terms.

For reprints contact: [reprints@medknow.com](mailto:reprints@medknow.com)

**How to cite this article:** Çildağ MB, Ertuğrul MB, Köseoğlu ÖF, Armstrong DG. A factor increasing venous contamination on bolus chase three-dimensional magnetic resonance imaging: Charcot neuroarthropathy. *J Clin Imaging Sci* 2018;8:13. Available FREE in open access from: <http://www.clinicalimagingscience.org/text.asp?2018/8/1/13/229380>

## Access this article online

### Quick Response Code:



**Website:**  
[www.clinicalimagingscience.org](http://www.clinicalimagingscience.org)

**DOI:** 10.4103/jcis.JCIS\_77\_17

vessels.<sup>[5]</sup> Furthermore in patients with diabetic foot, the inflammatory process recruits blood flow by reducing arteriolar resistance and thereby accelerating the arteriovenous transit.

Charcot neuropathic osteoarthropathy (CN) is a progressive disease affecting the bones, joints, and soft tissue of the foot and ankle, most commonly associated with diabetic neuropathy.<sup>[6,7]</sup> The pathogenesis of CN is presently poorly understood. There is no singular cause for the development of the CN, but there are factors that predispose to its development, as well as a number of likely precipitating events.<sup>[8]</sup> Jeffcoate et al. showed that the inflammatory cascade plays an important role in the development of this condition.<sup>[9]</sup> Hence, it has led us to believe that CN may increase venous contamination in MRA.

The study aimed to investigate whether venous contamination ratio on 3D bolus chase MR angiographies performed on diabetic patients differs between foot lesion and CN.

## MATERIALS AND METHODS

After approval from Adnan Menderes University ethics committee, lower extremity MRA analyses of patients with type 2 diabetes mellitus who had undergone lower extremity MRA between March 2014 and November 2016 were evaluated retrospectively. Extremities were divided into three groups as follows: without diabetic foot ulcers or CN (Group A), with only diabetic foot ulcers (Group B) and CN accompanying diabetic foot ulcers (Group C). The amount of venous contamination was divided into three. Classified as no venous contamination (without venous contamination), with venous contamination but no impact on quality (mild venous contamination), and nondiagnostic due to venous contamination (severe venous contamination). The relationship between venous contamination groups and extremity groups was investigated. All MRA procedures were performed on 1.5 T MR device (Achieva, Philips) and using bolus-chase 3D MRA technique.

Patients with insufficient image quality, with the known venous disease, and extremities which had undergone venous surgery and acute CN were excluded from the study. CN diagnosis was made based on clinical and direct graphy findings of the foot. Patients who had not radiography of foot were excluded from the study.

A multiphase 3D gradient-echo sequence with dynamic k space sampling was employed for the bolus-chase 3D MRA acquisition. 43 cm FOV, 3 mm thick slice with zero filling, 256 × 192 × 32 matrix, 62.5 kHz receiver bandwidth, 5.5/1.43 ms TR/TE, body receiver coil,

and 25 s per station was employed on all patients. A volume of 30 ml gadolinium was used with a power injector (Spectris, MedradInc) at 1 ml/s, followed by 20 ml saline at the same rate. The dynamic K-space sampling orders were optimized to enhance K-space center signal at all stations. A movable table was used. When common femoral arteries reached bolus peak (in the 2D acquisition), bolus-chase contrast was started.

## Statistical analysis

Statistical analysis was performed using Statistical Package for the Social Science software for windows (SPSS Inc., Chicago, IL, USA). Numerical variables were described as the mean ± standard deviations. Categorical variables were described as percentages (%). Following the descriptive statistics in data analysis, Chi-square independence test was performed to determine if there was any relationship between groups having more than two variables. Phi ( $\phi$ ) coefficient was calculated to determine the magnitude of the Chi-square value obtained in the analysis. A value of  $P < 0.05$  was considered statistically significant.

## RESULTS

MRA analysis with sufficient image quality was performed on 220 diabetic patients during the study period. Forty-four patients had one side BTK amputation. Therefore, one extremity of these patients were included in the study. BTK level venous contamination in a total of 396 extremities was evaluated from 3D MRA images. One hundred and forty-six of the patients (66.4%) were male, 74 (33.6%) were female. Their mean age was 66.4 (ranging 51–87). Two hundred and eighty-six extremities without diabetic foot (Group A) (72.2%), 66 extremities with only diabetic foot (Group B) (16.7%) and 44 extremities with CN accompanying diabetic foot (Group C) (11.1%) were observed. There were 133 extremities without venous contamination (33.6%), 222 extremities with venous contamination but no impact on diagnostic quality (56.1%) and 41 extremities nondiagnostic due to venous contamination (10.4%). There were 16 nondiagnostic analyses in Group A (5.6%), 10 nondiagnostic analyses in Group B (15.2%), and 15 nondiagnostic analyses in Group C (34.1%) [Table 1]. A difference between groups was observed in an analysis performed for the difference between extremity groups with regard to venous contamination ( $\chi^2 = 43.97$ ,  $P = 0.000$ ). The ratio of extremities without venous contamination in Group A, B, and C to all extremities was 36.4%, 39.4%, and 2.3%, respectively. In terms of venous contamination, Group C was found to be a statistically significant group ( $\chi^2 = 43.97$ ,  $df = 4$ ,  $P = 0.000$ , Cramers' value is 0.236 and effect size is medium).

## DISCUSSION

PAD is a group of disorders characterized by narrowing or occlusion of the arteries and patients with the diabetic foot disease have a greater prevalence of PAD. Previous studies have shown that 45%–85% of patients can be spared amputation if appropriate revascularization is performed by a reliable early diagnosis.<sup>[10,11]</sup> The accuracy of 3D gadolinium-enhanced-MRA in showing and grading peripheral vascular diseases was evaluated, and a sensitivity of 92% and specificity of 91% was determined.<sup>[12]</sup> Meta-analyses and systematic reviews support the diagnostic accuracy of MRA when compared to digital subtraction angiography (DSA).<sup>[13,14]</sup> Owen et al. showed that MRA is superior to DSA in the detection of outflow vessels suitable for distal bypass in patients with CLI.<sup>[15]</sup> Furthermore, a systematic review concluded that MRA is cost-effective in comparison to DSA.<sup>[16]</sup>

Bolus chase MRA is based on imaging of all extremities after a single injection of contrast material. Advantages of this method include faster examination, the easier timing of contrast injection, and fewer motion-related artifacts. Venous contamination may occur, especially at distal of the extremity with Bolus chase MR technique. Venous contamination is a serious problem in MRA. Excessive venous enhancement obscures arteries and limits the diagnostic utility of MRA. 3D images without venous signal may be obtained when the data were acquired before contrast returns to the veins. Patients with fast flow tend to have venous enhancement at a level below the knee. Furthermore, the inflammatory process recruits blood flow by reducing arteriolar resistance and thereby accelerating the arteriovenous transit. Wang et al.,<sup>[17]</sup> showed that legs with cellulitis have increased the incidence of venous contamination. Furthermore, Bassingthwaite et al. showed that capillary wall permeability could affect venous return more than flow rate.<sup>[18]</sup> Studies are being conducted to avoid venous contamination.<sup>[17,19,20]</sup> However, a method that would eliminate venous contamination has not

been identified. Diabetic ulcers due to the formation of an arteriovenous fistula at the capillary level may cause early venous return and venous contamination at MRA. BTK venous contamination was more frequently observed in the extremities with diabetic foot compared to the extremities without diabetic lesions in this study. However, no statistical significance was identified.

CN is a progressive disease affecting the bones, joints, and soft tissue of the foot and ankle. Of all patients with diabetes, 0.1%–7.5% have CN, and 29% of people with diabetes with peripheral neuropathy have CN.<sup>[21,22]</sup> In this study, venous contamination was more frequently detected in patients with CN accompanying diabetic foot when compared to the groups with and without diabetic foot [Figures 1-2]. Literature research did not reveal any information that Charcot joint increases venous contamination in MRA. However, we considered that inflammatory process which might play a role in the pathogenesis of CN may increase permeability and that venous contamination is increased as secondary to this effect. Recent years, time-resolved MRA techniques use to improve temporal resolution enables clear separation of arterial inflow from venous drainage, allowing the possibility of acquiring information concerning contrast material arrival time and flow direction. In addition, much smaller doses of contrast can also be used than with conventional CE-MRA. However, there were no data about using time-resolved MRA techniques in patients with CN.<sup>[23,24]</sup>

Limitations of this study were the lack of CN cases without diabetic foot ulcers and patients without diabetes. Moreover, the other limitation was unused of time-resolved MRA techniques for imaging.

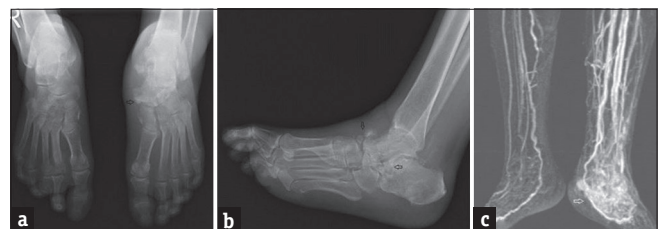## CONCLUSION

PAD is frequently observed in patients with diabetes, especially more frequent in diabetic cases with diabetic foot. Pretreatment evaluation of BTK arteries is necessary because BTK arterial involvement is more prevalent

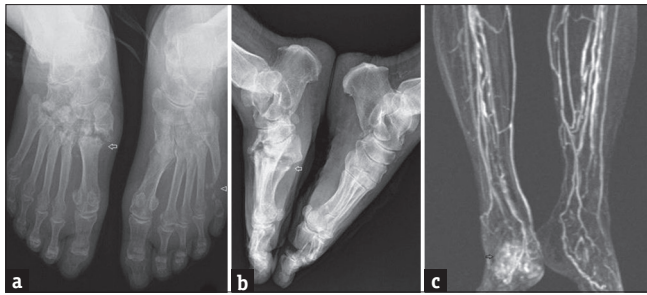
**Table 1: Venous contamination ratios belong to groups**

	Without venous contamination, n (%)	Mild venous contamination, n (%)	Severe venous contamination, n (%)
Group A (n=286)	104 (36.4)	166 (58)	16 (5.6)
Group B (n=66)	26 (39.4)	30 (45.5)	10 (15.2)
Group C (n=44)	3 (2.3)	26 (59.1)	15 (34.1)

$\chi^2$ : 43.97, df: 4,  $P < 0.001$ , Cramer's value is 0.236 and effect size is medium



**Figure 1:** (a-c) A 60-year-old male who had Charcot neuroarthropathy at left talonavicular and talocalcaneal joints. (a and b) In anteroposterior and lateral graphies, arrows indicate destructive changes at left talonavicular and talocalcaneal joints. (c) In three-dimensional magnetic resonance angiography, there was severe venous contamination at left below-the-knee (Group C) and there was mild venous contamination at right below-the-knee (Group A).



**Figure 2:** (a-c) A 67-year-old female who had Charcot neuroarthropathy at right tarsometatarsal joints. (a and b) In anteroposterior (a) and lateral graphies (b), arrows show destructive changes in tarso-metatarsal joints and articular disorganization, midfoot collapse, and talar plantar flexion (arrow in Figure b). Also, 5. metatarsal head resorption seen on left foot (arrowhead in Figure a). (c) Bolus-chase three-dimensional magnetic resonance angiography shows severe venous contamination at right below-the-knee (Group C) and there was mild venous contamination at left below-the-knee (Group A).

in diabetic cases. MRA has replaced conventional angiography in the evaluation of lower extremity arteries in recent years. However, venous contamination significantly limits evaluation of BTK arteries through MRA.

This study showed that CN significantly increases venous contamination. It might be useful to evaluate lower extremity arteries of patients with diabetes and CN with time-resolved MRA techniques or computed tomography which is another noninvasive method, also taking into consideration renal functions.

#### Financial support and sponsorship

Nil.

#### Conflicts of interest

There are no conflicts of interest.

#### REFERENCES

- Gibbons GW, Freeman D. Vascular evaluation and treatment of the diabetic. *Clin Podiatr Med Surg* 1987;4:377-81.
- Towne JB. Management of foot lesions in the diabetic patient. In: Rutherford RB, editor. *Vascular Surgery*. Philadelphia: W.B. Saunders Company; 2000. p. 1093.
- Faglia E, Clerici G, Clerissi J, Mantero M, Caminiti M, Quarantiello A, et al. When is a technically successful peripheral angioplasty effective in preventing above-the-ankle amputation in diabetic patients with critical limb ischaemia? *Diabet Med* 2007;24:823-9.
- Zhang H, Maki JH, Prince MR. 3D contrast-enhanced MR angiography. *J Magn Reson Imaging* 2007;25:13-25.
- Graziani L, Silvestro A, Bertone V, Manara E, Andreini R, Sigala A, et al. Vascular involvement in diabetic subjects with ischemic foot ulcer: A new morphologic categorization of disease severity. *Eur J Vasc Endovasc Surg* 2007;33:453-60.
- Ertugrul BM, Lipsky BA, Savk O. Osteomyelitis or Charcot neuro-osteopathy? Differentiating these disorders in diabetic patients with a foot problem. *Diabet Foot Ankle* 2013;4:1-8.
- Schoots IG, Slim FJ, Busch-Westbroek TE, Maas M. Neuro-osteopathy of the foot-radiologist: Friend or foe? *Semin Musculoskelet Radiol* 2010;14:365-76.
- Rogers LC, Frykberg RG, Armstrong DG, Boulton AJ, Edmonds M, Van GH, et al. The charcot foot in diabetes. *Diabetes Care* 2011;34:2123-9.
- Jeffcoate WJ, Game F, Cavanagh PR. The role of proinflammatory cytokines in the cause of neuropathic osteopathy (acute Charcot foot) in diabetes. *Lancet* 2005;366:2058-61.
- Pomposelli FB, Kansal N, Hamdan AD, Belfield A, Sheahan M, Campbell DR, et al. A decade of experience with dorsalis pedis artery bypass: Analysis of outcome in more than 1000 cases. *J Vasc Surg* 2003;37:307-15.
- Reiber GE, Boyko EJ, Smith DG. Lower extremity foot ulcers and amputations in diabetes. In: Harris MI, Stern MP, editors. *Diabetes in America*. Bethesda, MD: U.S. Government Printing Office; 1995. p. 409-28.
- Ersoy H, Zhang H, Prince MR. Peripheral MR angiography. *J Cardiovasc Magn Reson* 2006;8:517-28.
- Koelemay MJ, Lijmer JG, Stoker J, Legemate DA, Bossuyt PM. Magnetic resonance angiography for the evaluation of lower extremity arterial disease: A meta-analysis. *JAMA* 2001;285:1338-45.
- Nelemans PJ, Leiner T, de Vet HC, van Engelshoven JM. Peripheral arterial disease: Meta-analysis of the diagnostic performance of MR angiography. *Radiology* 2000;217:105-14.
- Owen AR, Robertson IR, Annamalai G, Roditi GH, Edwards RD, Murray LS, et al. Critical lower-limb ischemia: The diagnostic performance of dual-phase injection MR angiography (including high-resolution distal imaging) compared with digital subtraction angiography. *J Vasc Interv Radiol* 2009;20:165-72.
- Berry E, Kelly S, Westwood ME, Davies LM, Gough MJ, Bamford JM, et al. The cost-effectiveness of magnetic resonance angiography for carotid artery stenosis and peripheral vascular disease: A systematic review. *Health Technol Assess* 2002;6:1-55.
- Wang Y, Chen CZ, Chabra SG, Winchester PA, Khilnani NM, Watts R, et al. Bolus arterial-venous transit in the lower extremity and venous contamination in bolus chase three-dimensional magnetic resonance angiography. *Invest Radiol* 2002;37:458-63.
- Bassingthwaite JB, Chan IS, Wang CY. Computationally efficient algorithms for convection-permeation-diffusion models for blood-tissue exchange. *Ann Biomed Eng* 1992;20:687-725.
- Maki JH, Wilson GJ, Cartright SD, Bastawrous S. Patient-specific timing for bolus-chase peripheral MR angiography. *J Magn Reson Imaging* 2016;43:249-60.
- Zhang HL, Ho BY, Chao M, Kent KC, Bush HL, Faries PL, et al. Decreased venous contamination on 3D gadolinium-enhanced bolus chase peripheral mr angiography using thigh compression. *AJR Am J Roentgenol* 2004;183:1041-7.
- Chisholm KA, Gilchrist JM. The Charcot joint: A modern neurologic perspective. *J Clin Neuromuscul Dis* 2011;13:1-3.
- Rajbhandari SM, Jenkins RC, Davies C, Tesfaye S. Charcot neuroarthropathy in diabetes mellitus. *Diabetologia* 2002;45:1085-96.
- Razek AA, Gaballa G, Megahed AS, Elmogy E. Time resolved imaging of contrast kinetics (TRICKS) MR angiography of arteriovenous malformations of head and neck. *Eur J Radiol* 2013;82:1885-91.
- Grist TM, Mistretta CA, Strother CM, Turski PA. Time-resolved angiography: Past, present, and future. *J Magn Reson Imaging* 2012;36:1273-86.