

# A case of leiomyosarcoma of the common femoral artery

Daniel Nguyen, BS, Luis R. Leon, MD, FACS, John P. Pacanowski, MD, MBA, and Scott S. Berman, MD, MHA, FACS, DFSVS, Tucson, Ariz

## ABSTRACT

Leiomyosarcomas are rare malignant tumors of smooth muscle cell origin with those originating from blood vessels accounting for <1%. We report the unusual case of a leiomyosarcoma originating in the wall of the common femoral artery, highlighting the management decisions for vascular tumors and providing a brief literature review for these unusual malignancies. (*J Vasc Surg Cases and Innovative Techniques* 2021;7:291-4.)

**Key words:** Arterial tumor; Leiomyosarcoma

Malignant tumors primarily originating from blood vessels are rare and include angiosarcomas, Kaposi sarcoma, and hemangiopericytoma, which originate from endothelial cells and adventitial cells. Leiomyosarcomas (LMS) of the blood vessels originating from vascular smooth muscle cells are an even more unusual form of vascular tumor and more commonly originate from veins. In the present report, we have described an unusual case of an LMS originating from the common femoral artery and provide a brief literature review of this rare form of malignancy. The patient provided written informed consent for the report of her case and related imaging studies.

## CASE REPORT

The patient was a 91-year-old woman who had presented with a 6-week history of significant right groin pain related to positioning and activity. Her medical history was significant for long-term anticoagulation therapy for management of atrial fibrillation. Magnetic resonance imaging (MRI) of her right hip ordered by her primary care physician demonstrated either nonspecific right inguinal lymph node enlargement or a pseudoaneurysm (Fig 1, A). An ultrasound examination identified a 37- × 26- × 31-mm, hypoechoic, soft tissue mass interposed between the right common femoral artery and vein (Fig 1, B). Her physical examination revealed tenderness on palpation of the right inguinal region without swelling or lymphadenopathy. She was referred for oncologic examination and underwent a needle biopsy of the mass, with findings suspicious for LMS.

From the Pima Heart and Vascular, Section of Vascular Surgery, The University of Arizona.

Author conflict of interest: none.

Correspondence: Scott S. Berman, MD, MHA, FACS, DFSVS, Pima Heart and Vascular, Section of Vascular Surgery, The University of Arizona, 1815 W St Mary's Rd, Tucson, AZ 85745 (e-mail: [bermanaz@gmail.com](mailto:bermanaz@gmail.com)).

The editors and reviewers of this article have no relevant financial relationships to disclose per the Journal policy that requires reviewers to decline review of any manuscript for which they may have a conflict of interest.

2468-4287

© 2021 The Authors. Published by Elsevier Inc. on behalf of Society for Vascular Surgery. This is an open access article under the CC BY-NC-ND license (<http://creativecommons.org/licenses/by-nc-nd/4.0/>).

<https://doi.org/10.1016/j.jvs.2021.02.004>

Computed tomography (CT) of the chest, abdomen, and pelvis showed no evidence of metastatic disease.

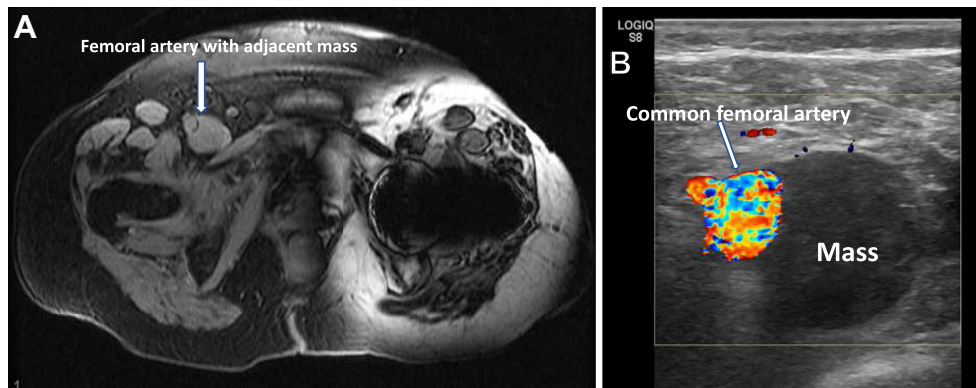
The patient underwent surgical resection of the LMS. A vertical groin incision was made through the skin and subcutaneous tissue, revealing prominent matting of the inguinal lymph nodes, with a soft tissue mass visualized that emanated from the medial wall of the right common femoral artery (Fig 2, A). The tumor was resected by dividing the common femoral artery just beyond the takeoff of the epigastric vessels proximally and distally just above the femoral bifurcation. Vascular reconstruction was accomplished with an 8-mm expanded polytetrafluoroethylene interposition graft (W. L. Gore and Associates, Flagstaff, Ariz; Fig 2, B). The tumor, with proximal and distal margins of the common femoral artery (Fig 2, C), was sent for pathologic examination with a separate specimen of the excised inguinal lymph node tissue.

Sectioning revealed the tumor had emanated from the vessel wall. The proximal and distal arterial margins were free of tumor. On histopathologic examination, the tumor specimen demonstrated a fasciculated spindle cell configuration with tumor cell atypia, hypercellularity, and a variable mitotic grade with a rate of two mitotic figures per 10 high power fields. Necrosis was not observed. Immunohistochemically, the tumor cells were strongly and diffusely positive for desmin and smooth muscle actin (Fig 3). Staining was negative for S-100, typical of sarcomas. In addition, the proliferation index detected by Ki-67 marker testing was 30% to 40%. Thus, the final diagnosis was LMS of the right common femoral artery.

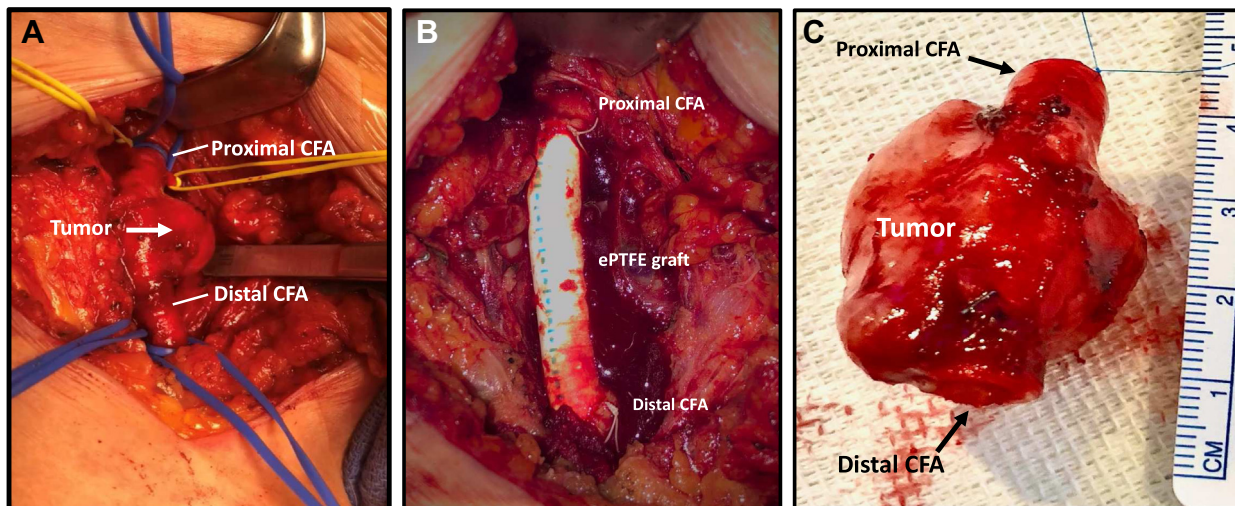
The patient experienced prolonged lymphatic drainage from her closed drainage system that had resolved after 4 to 6 weeks. She had an otherwise uneventful long-term recovery with only mild right-lower extremity-dependent edema. Her oncologist did not believe any adjuvant therapy was required because the surgical margins were negative for tumor. Recent CT scanning demonstrated no evidence of tumor recurrence at 2 years postoperatively (Fig 4).

## DISCUSSION

LMSs are rare malignant tumors of smooth muscle origin generally found in the uterus, gastrointestinal tract, and retroperitoneum.<sup>1</sup> Primary soft tissue tumors arising from blood vessels are extremely rare and account



**Fig 1. A,** Magnetic resonance imaging (MRI) study of the right groin demonstrating a well-circumscribed structure between the femoral artery and femoral vein measuring 2.4 cm. **B,** Color flow Doppler imaging study showing an hypoechoic mass adjacent to the right common femoral artery, with features consistent with a soft tissue tumor.

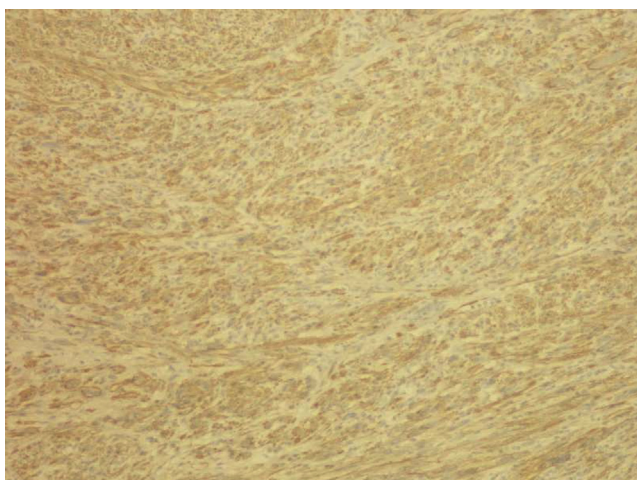


**Fig 2. A,** Exposure of the right common femoral artery (CFA) with tumor visible emanating from the medial wall. **B,** Resected leiomyosarcoma of the right CFA, with a Prolene suture marking the proximal margin. **C,** Right femoral artery reconstruction using an 8-mm expanded polytetrafluoroethylene (ePTFE) interposition graft.

for <1% of all malignancies.<sup>2</sup> Among them, vascular LMSs only represent 2% of cases and will involve the veins roughly five times more frequently than the arteries. In their case report of an LMS originating from the profunda femoris artery, Sakpal et al<sup>2</sup> reported that arterial LMSs constituted 21% of cases (18 of 86), and most had originated from the pulmonary artery. In addition to the pulmonary artery, arterial LMSs have been reported to arise from the aorta and carotid, subclavian, renal, splenic, iliac, common femoral, superficial femoral, and popliteal arteries. Sakpal et al<sup>2</sup> identified a total of eight cases of

LMS originating from the femoral artery, including cases reported by Kevorkian and Cento,<sup>3</sup> Porcellini et al,<sup>4</sup> Gramith and Smith,<sup>5</sup> and Meulman and Graham.<sup>6</sup>

Vascular LMSs typically occur in adults aged 37 to 80 years, without a gender predilection, although several cases have been reported in children.<sup>7</sup> The symptoms associated with arterial LMSs vary greatly according to the location of the tumor. Most peripheral arterial LMSs will present with claudication. Depending on the location of these tumors, they can compress adjacent nerves and cause neurologic symptoms.



**Fig 3.** Histologic slides of resected tumor after immunohistochemical staining for smooth muscle actin (CD117) at  $\times 40$  magnification.

The diagnostic evaluation for a tumor suspected to be LMS should begin with MRI of the lesion and CT scanning of the chest, abdomen, and pelvis. MRI should be performed to illustrate the anatomic extent of the tumor and evaluate the possible involvement of adjacent bones, nerves, and/or vascular structures. CT of the chest, abdomen, and pelvis is used to evaluate for potential metastatic disease because vascular LMSs have a greater rate of synchronous metastases than other forms of LMS (36% vs 15%).<sup>8</sup> A biopsy is necessary to establish the diagnosis of LMS. A CT-guided needle biopsy is favored over open incisional biopsy because the former can be accomplished with less morbidity. The differential diagnosis includes hemangioma, littoral cell angioma, lymphangioma, lymphoma, angiosarcoma, metastases, and other rare forms of sarcomas.<sup>8</sup>

Pathologically, a LMS can be identified through standard hematoxylin-eosin and immunohistochemical staining. The histologic appearance of a vascular LMS will typically exhibit a highly cellular field with abundant pink to deep red cytoplasm and centrally located cigar-shaped nuclei. Classically, myofibrils will be present running longitudinally along the length of the cell. Size, atypia, necrosis, and mitoses per high-power field are also indicators to differentiate between a malignant LMS and a benign smooth muscle tumor. Immunohistochemical staining will support the diagnosis of LMS by demonstrating the presence of muscle-specific markers, including desmin and smooth muscle actin. Exclusion of metastatic vascular melanomic-type lesions can be

achieved by confirming the absence of S-100 protein and HMB-45. For LMS, the prognosis is determined by the local invasiveness.

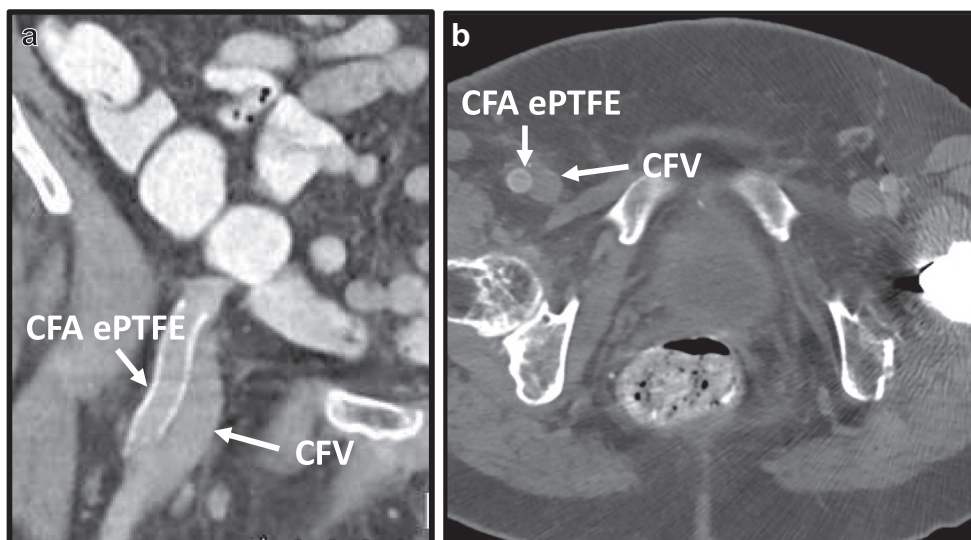
Surgical resection is generally advised for treatment of vascular LMSs. However, achieving local control of vascular LMSs via surgery can be complicated in some cases owing to their close proximity to vital structures. Radiation therapy can be considered as an alternative option to achieve local control. Radiation therapy can also be used as adjuvant therapy after resection of the tumor. The sensitivity of sarcoma to chemotherapy has been considered poor, and this also holds true for LMSs.<sup>9</sup> Gow et al<sup>10</sup> reported that untreated vascular LMSs are associated with aggressive tumor growth and the earlier development of metastasis compared with other soft tissue tumors. Additionally, Gravel et al<sup>11</sup> postulated that arterial LMSs are more aggressive than LMSs of other origins owing to their direct seeding to an artery. Our review of the limited research available on these rare tumors yielded reports of metastasis to the lungs, bone, and lymph nodes, occurring in 60%, as documented by Kevorkian and Cento.<sup>3</sup>

The prognosis for vascular LMS tends to be poor, with Castro et al<sup>12</sup> reporting a 5-year survival rate of 32% to 37%. Italiano et al<sup>8</sup> also reported significantly worse median metastasis-free survival and overall survival for those with vascular LMSs compared with LMSs of other origins. Information on the survival rates for patients with primary femoral artery LMS is severely limited owing to its rarity. Our review only yielded eight patient cases. No treatment was reported for two of these patients. The other six patients had undergone surgery, with two of them also undergoing radiation therapy. One of the patients who had undergone only surgical resection had died at 7 months, and another patient who had undergone both surgery and radiation therapy had developed recurrence and had died at 16 months.

## CONCLUSIONS

Few clinical descriptions of peripheral arterial LMSs have been documented because the condition is exceedingly rare. Owing to the complexity of its occurrence, management of arterial LMSs should be preceded by MRI and CT to evaluate the local and systemic extent of the disease, respectively. Complete surgical resection is the recommended form of treatment to achieve local control. Depending on the histologic findings, radiation therapy can be offered to patients for palliative therapy after resection of the tumor.





**Fig 4.** Computed tomography (CT) scan of right common femoral artery (CFA) reconstruction using expanded polytetrafluoroethylene (ePTFE) interposition graft and adjacent common femoral vein (CFV) 2 years after leiomyosarcoma (LMS) resection. **a**, Coronal view. **b**, Axial view.

## REFERENCES

- Piovanello P, Viola V, Costa G, Carletti M, Cecera A, Turchetta F, et al. Locally advanced leiomyosarcoma of the spleen: a case report and review of the literature. *World J Surg Oncol* 2007;5:135.
- Sakpal SV, Mehta R, Babel N, Chamberlain RS. Peripheral artery leiomyosarcoma. *J Vasc Surg* 2009;49:217-21.
- Kevorkian J, Cento DP. Leiomyosarcoma of large arteries and veins. *Surgery* 1973;73:390-400.
- Porcellini M, D'Armiento FP, Spinetti F, Anniciello A, Bracale G. Delayed diagnosis of leiomyosarcoma of the common femoral artery after endovascular repair. *J Endovasc Ther* 2003;10:846-8.
- Gramith F, Smith L. Ultrasound demonstration of a superficial femoral artery leiomyosarcoma. *J Ultrasound Med* 1989;8:269-72.
- Meulman NB, Graham JC. Leiomyosarcoma of the superficial femoral artery presenting as a ruptured aneurysm. *Aust N Z J Surg* 1991;61:853-5.
- de Saint Aubain Somerhausen N, Fletcher C. Leiomyosarcoma of soft tissue in children: clinicopathologic analysis of 20 cases. *Am J Surg Pathol* 1999;23:755.
- Italiano A, Toulmonde M, Stoeckle E, Kind M, Kantor G, Coindre J-M, et al. Clinical outcome of leiomyosarcomas of vascular origin: comparison with leiomyosarcomas of other origin. *Ann Oncol* 2010;21:1915-21.
- Clark MA, Fisher C, Judson I, Thomas JM. Soft-tissue sarcoma in adults. *N Engl J Med* 2005;353:701-11.
- Gow CH, Liaw YS, Chang YL, Chang YC, Yang RS. Primary vascular leiomyosarcoma of the femoral vein leading to metastases of scalp and lungs. *Clin Oncol (R Coll Radiol)* 2005;17:201.
- Gravel G, Yevich S, Tselikas L, Mir O, Teriitehau C, De Baère T, et al. Percutaneous thermal ablation: a new treatment line in the multidisciplinary management of metastatic leiomyosarcoma? *Eur J Surg Oncol* 2017;43:181-7.
- Castro WH, Jerosch J, de Fijter CW, Labrie A, Winkelmann W. Diagnosis and therapy for a leiomyosarcoma of vascular origin. *Acta Orthop Belg* 1989;55:162-6.

Submitted Dec 4, 2020; accepted Feb 16, 2021.